


plasmatek

Micro Plasma Coherent for
non surgical blepharoplasty
periocular wrinkles treatment
and more

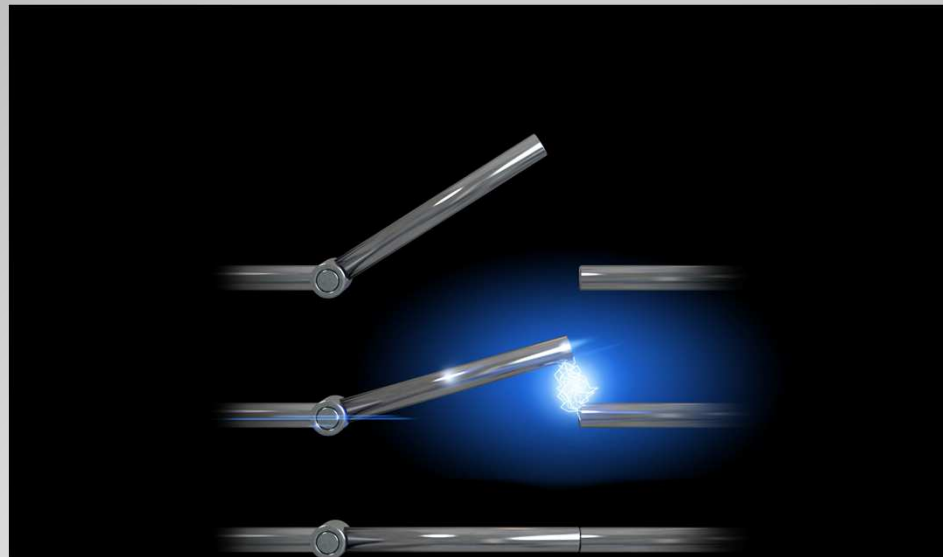


leasemedica

The electric arc is a phenomenon that occurs during the operations of opening and closing of an electrical circuit.




Moving slowly away two electrodes, one can observe that in the early stages of this operation the distance between them may not be sufficient to guarantee the necessary dielectric strength required for the interruption of the current flow.



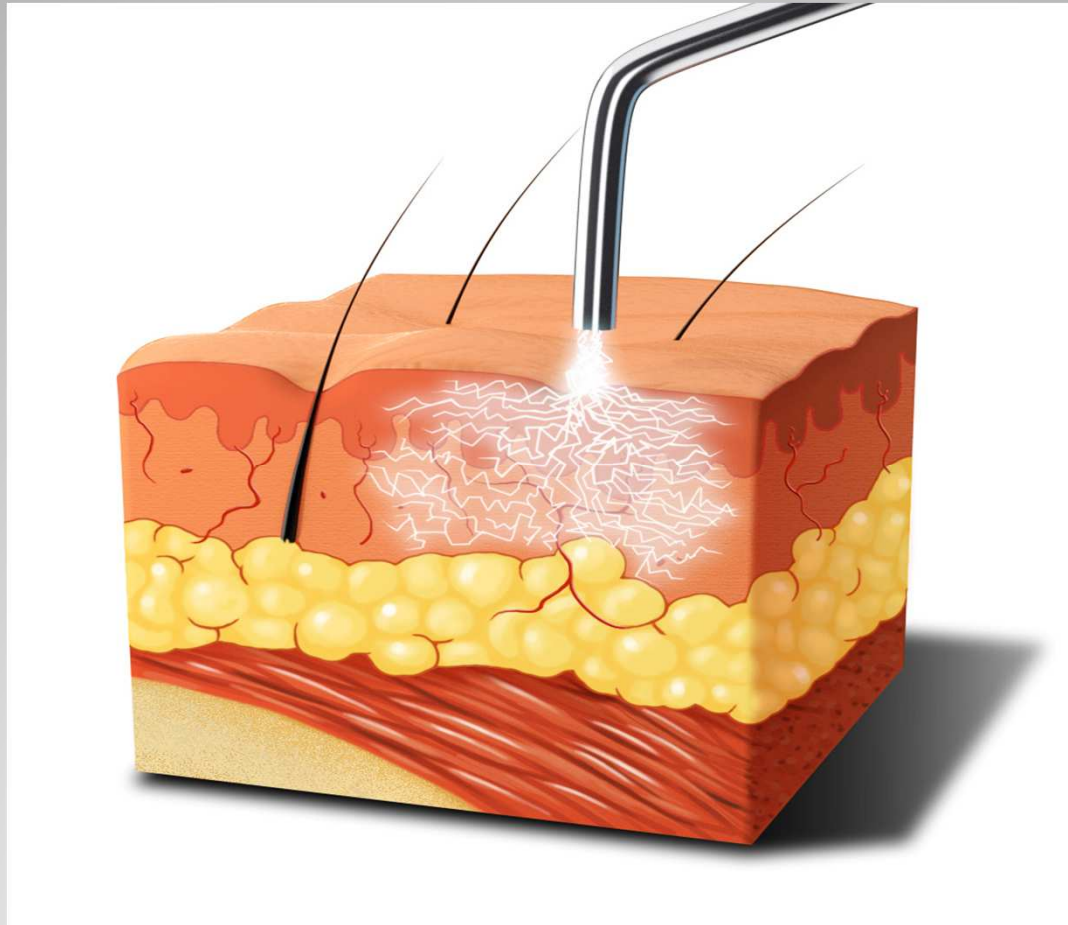
It occurs a perforation of the dielectric (air) and there is therefore the formation of the electric arc. The air between the electrodes therefore becomes conductive

It consists of a light beam generated by the ionization of the air.



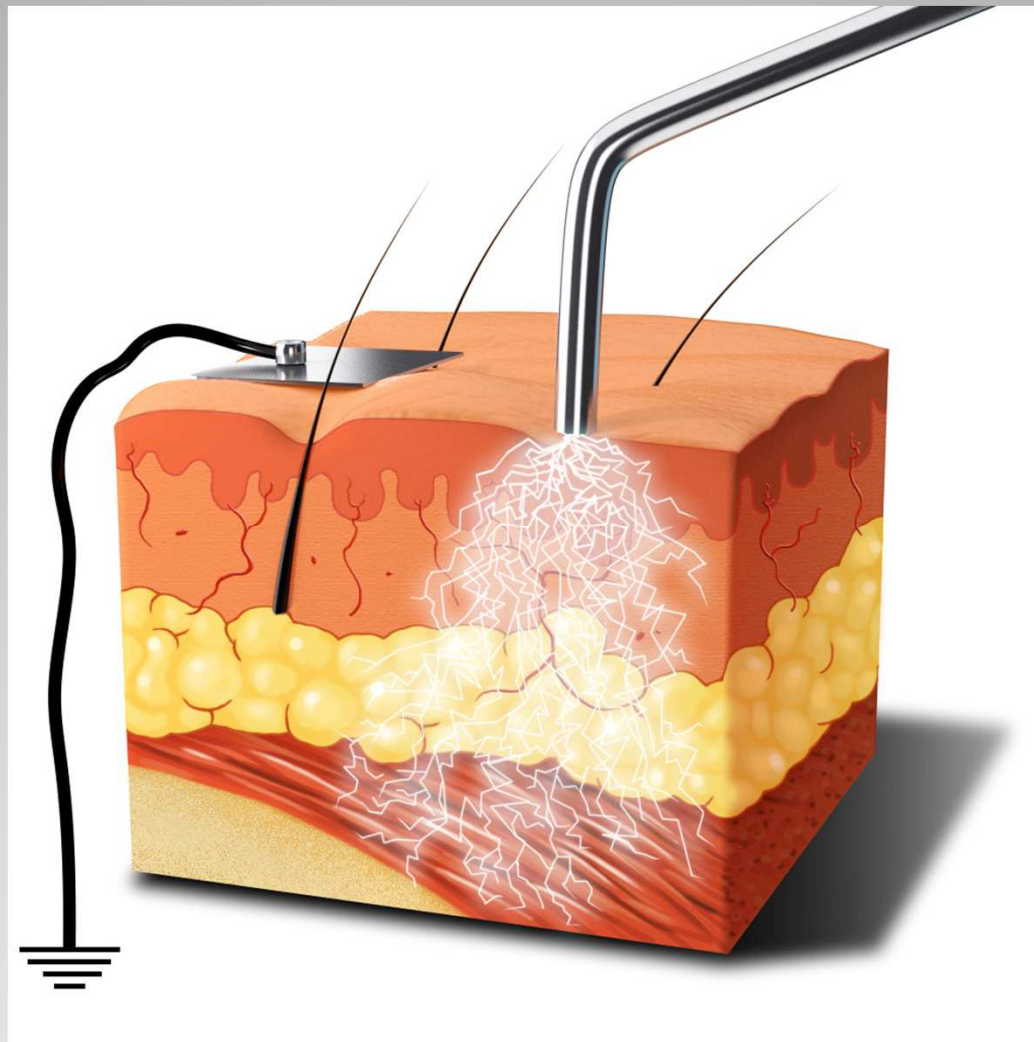
WHAT WILL CAUSE THE ARC ON THE SKIN?

**Skin evaporation by epidermolysis with
superficial spreading**

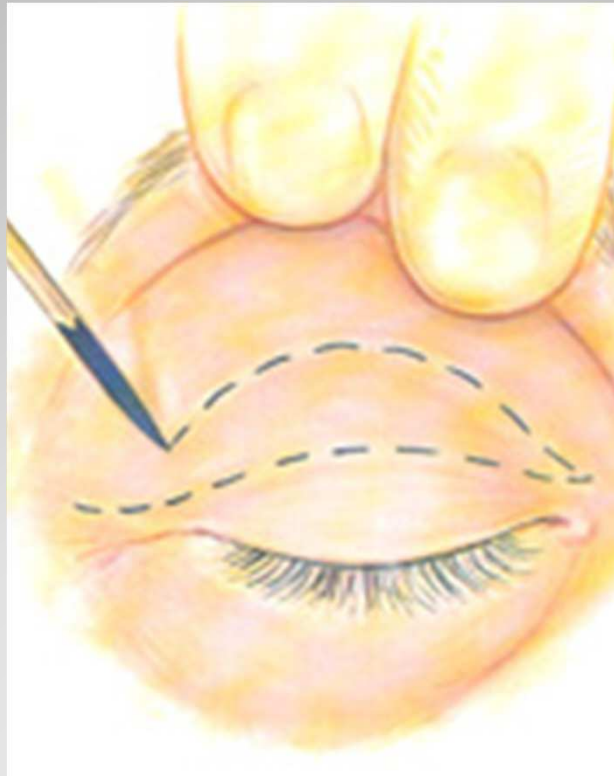


WHAT IS THE DIFFERENCE WITH A COMMON ELECTROCOAGULATOR?

Large skin evaporation
Depth diffusion



BLEPHAROPLASTY



**The surgical blepharoplasty can be
regarded as a removal of the tissues**

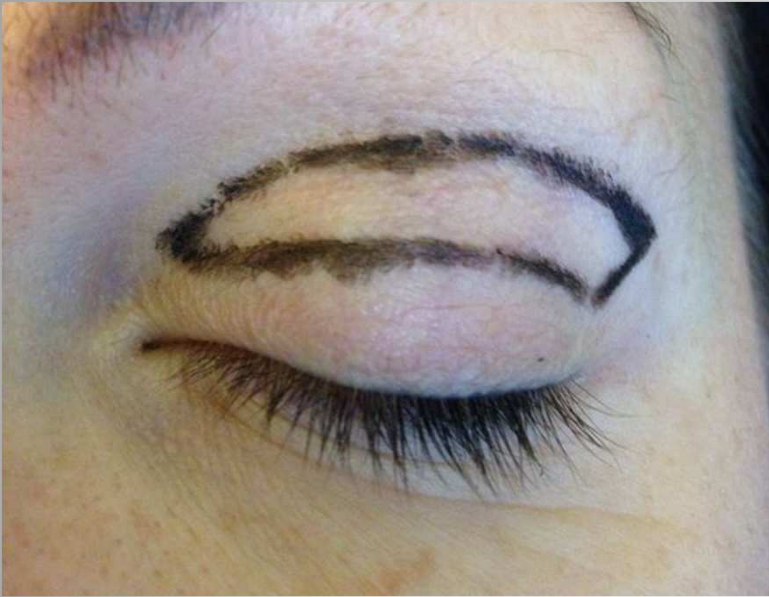

**SKIN RESECTION
BLEFAROPLASTY**

The non surgical blepharoplasty can be regarded as a contraction of the tissues



**SKIN CONTRACTION
BLEFAROPLASTY**



The skin is not removed

It creates a contraction of the skin itself

Treatments

Number of patients treated: 56 (53 F / 3M)

Aged between 39 and 70 years

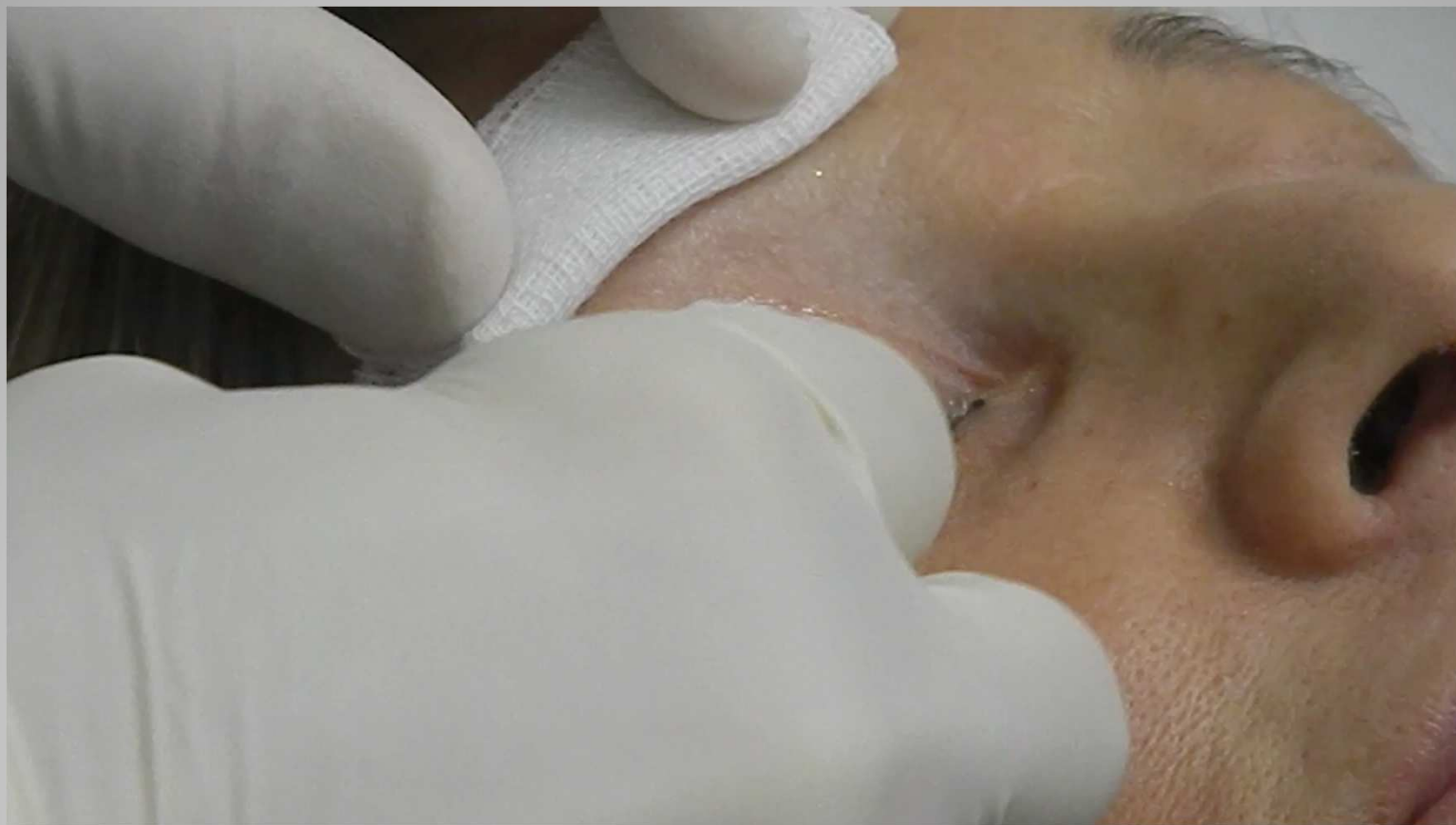Patients treated one time: 11

Patients treated twice: 15

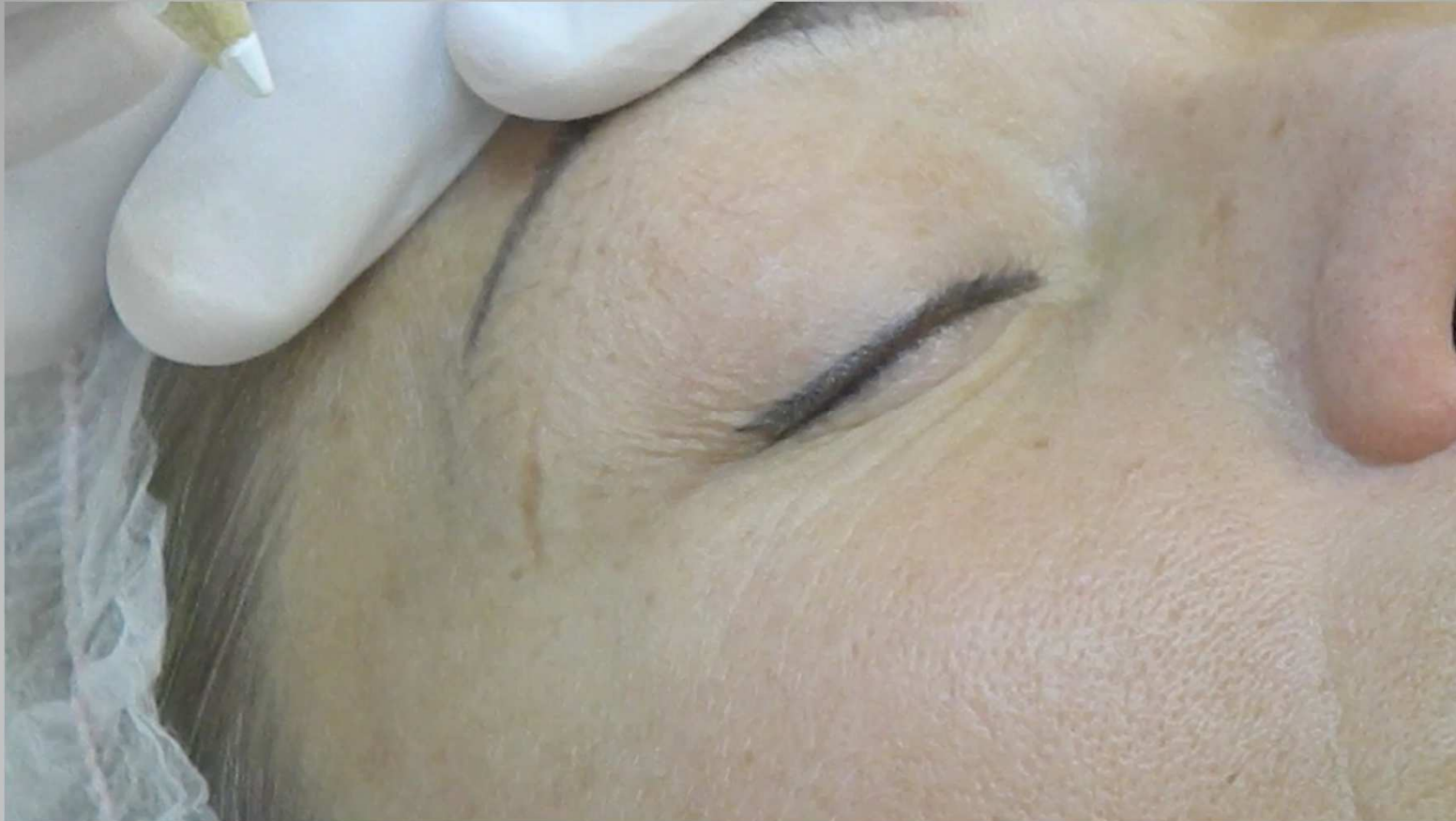Patients treated three times: 30

Indications

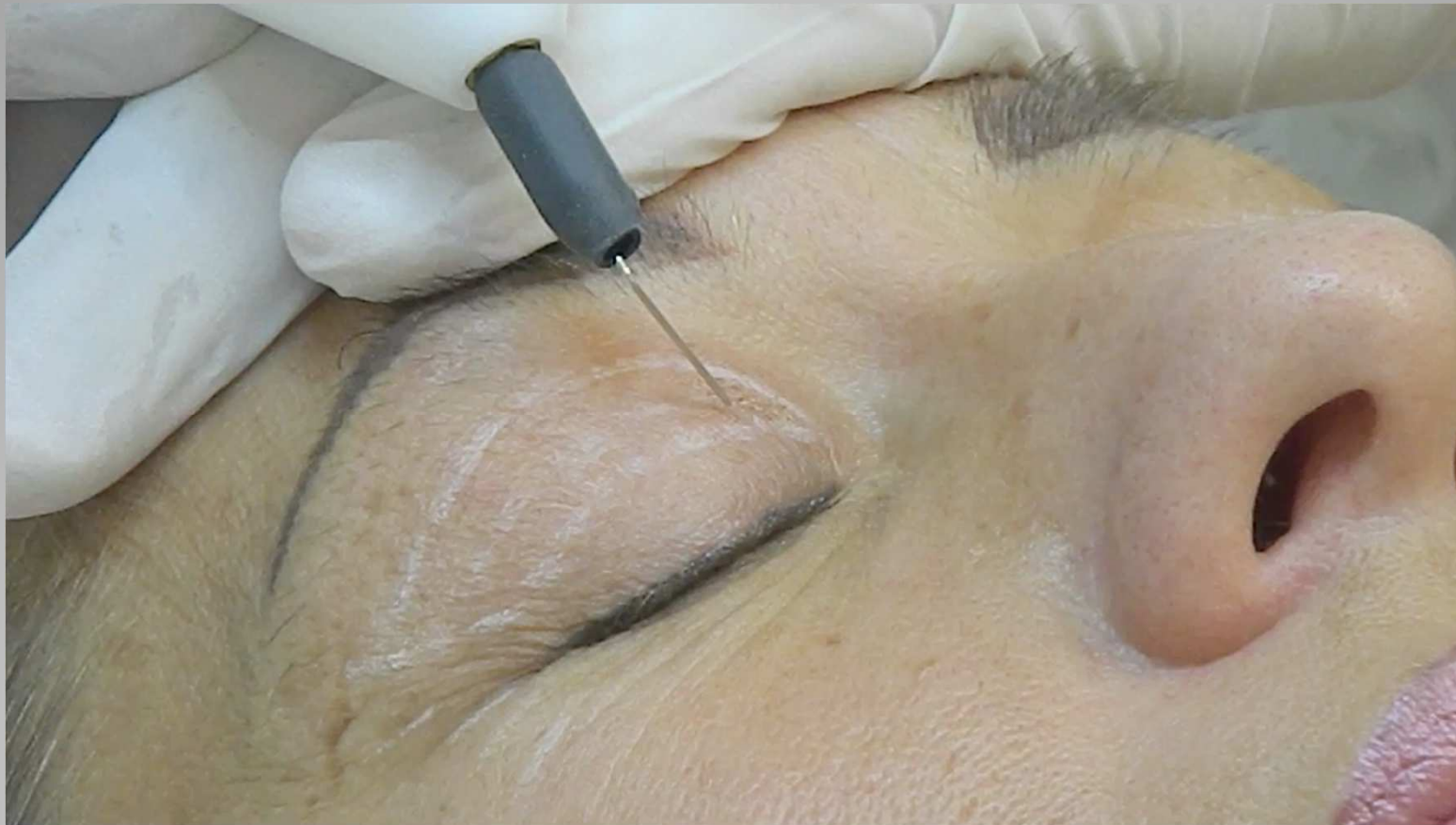- Minimum skin excess of the eyelid sup. or shorter in the absence of lipoptosy
- Rugosity and eyelid laxity
- Patients who refuse surgery
- Patients attracted from minimally invasive procedures
- Patients with crow's feet who refuse Botox



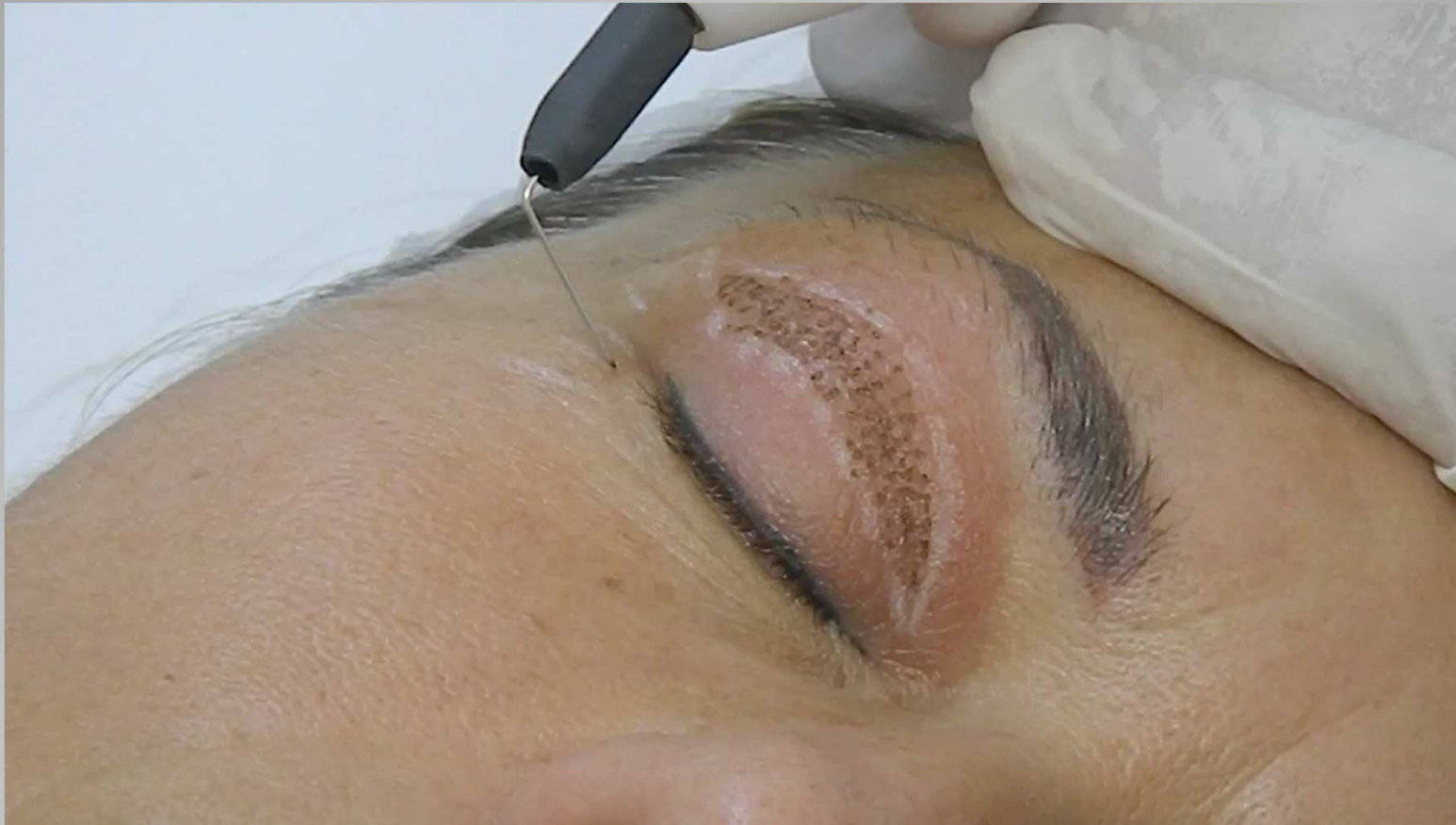anesthesia



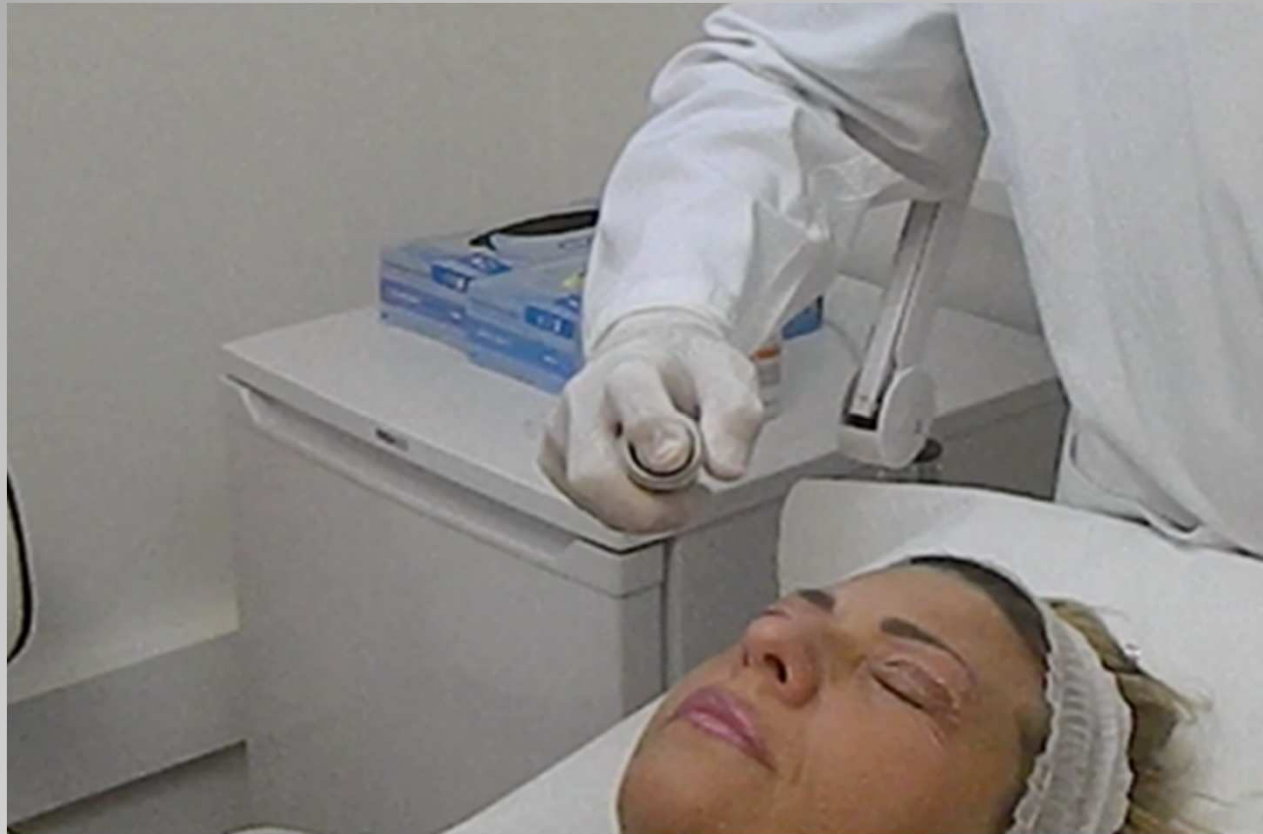drawing



the procedure: vaporization point



the procedure: crow's feet



the dressing

At home

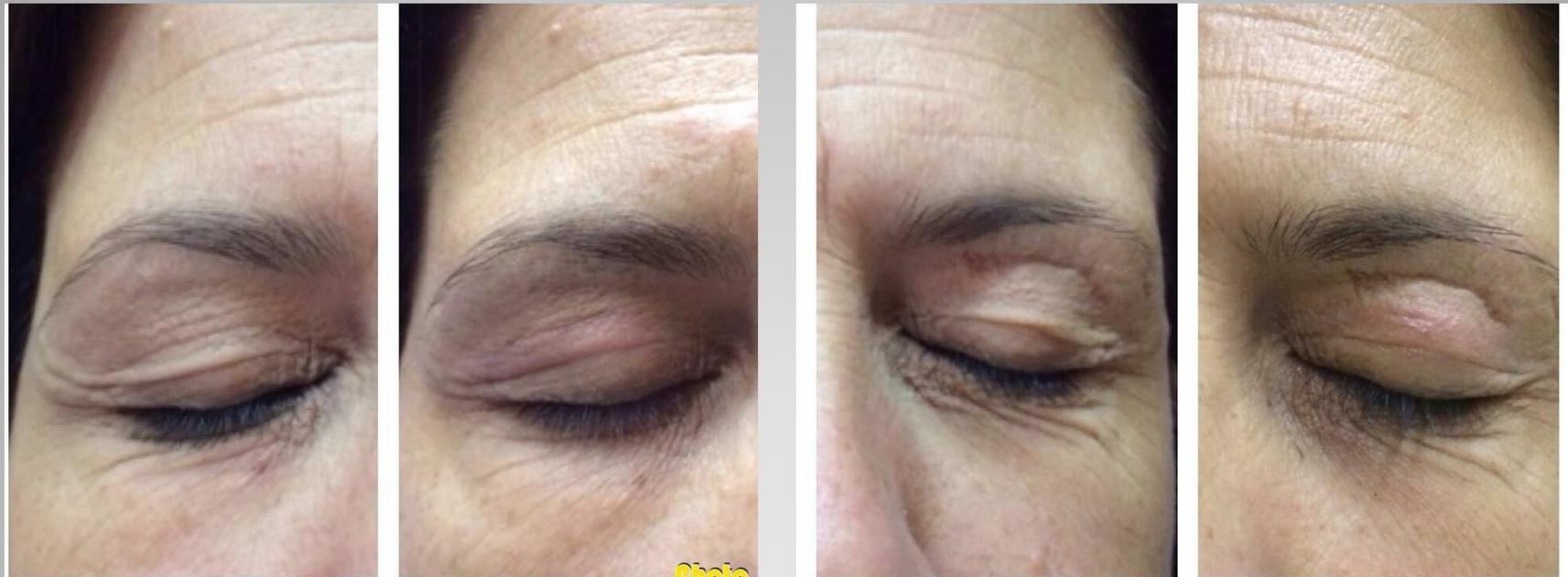Thermal water: many applications for 2 days
Corticosteroid therapy

Results


In all patients it was observed an objective improvement of the initial condition in terms of surface roughness, skin tension and reduction of the fold eyelid

The level of improvement was directly proportional to the number of treatments carried out

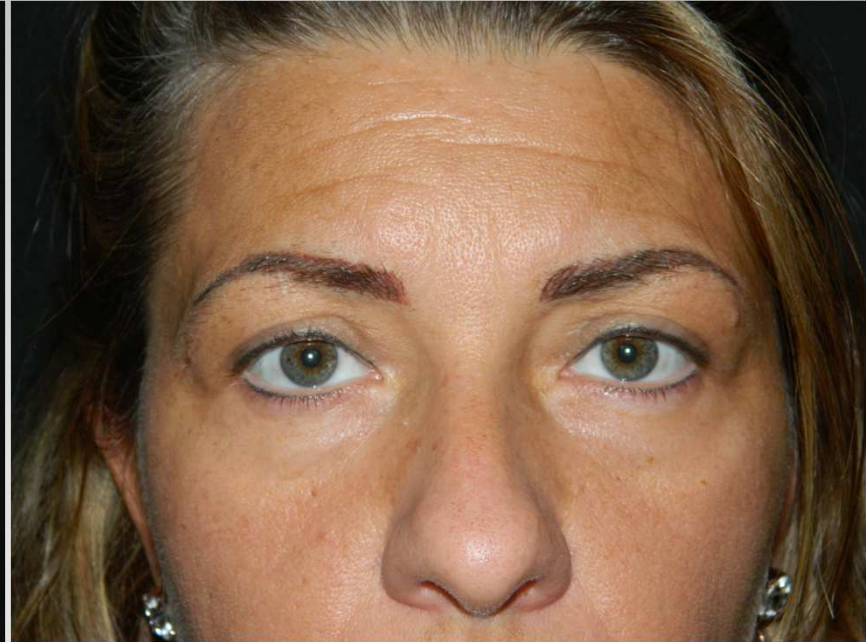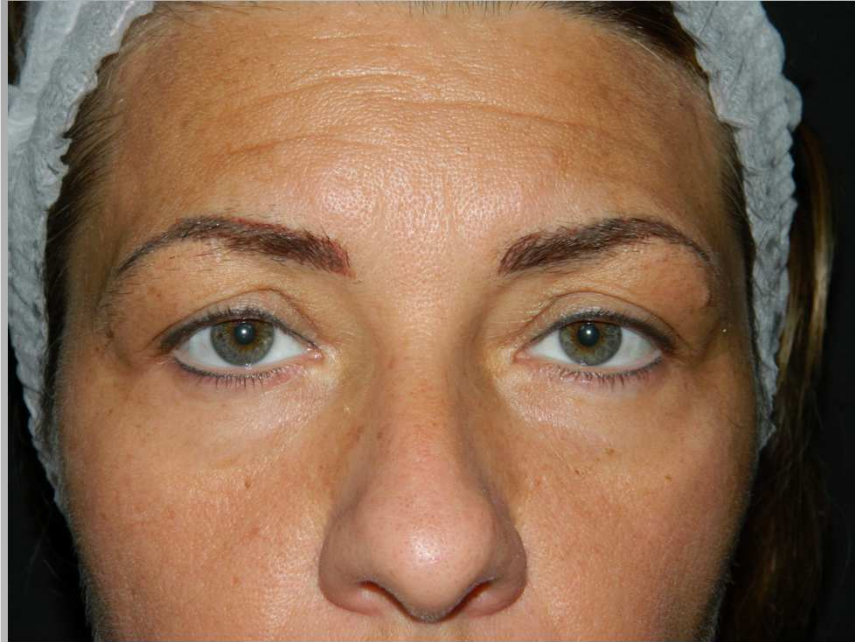Patients treated with a single session were suffering from minor imperfection



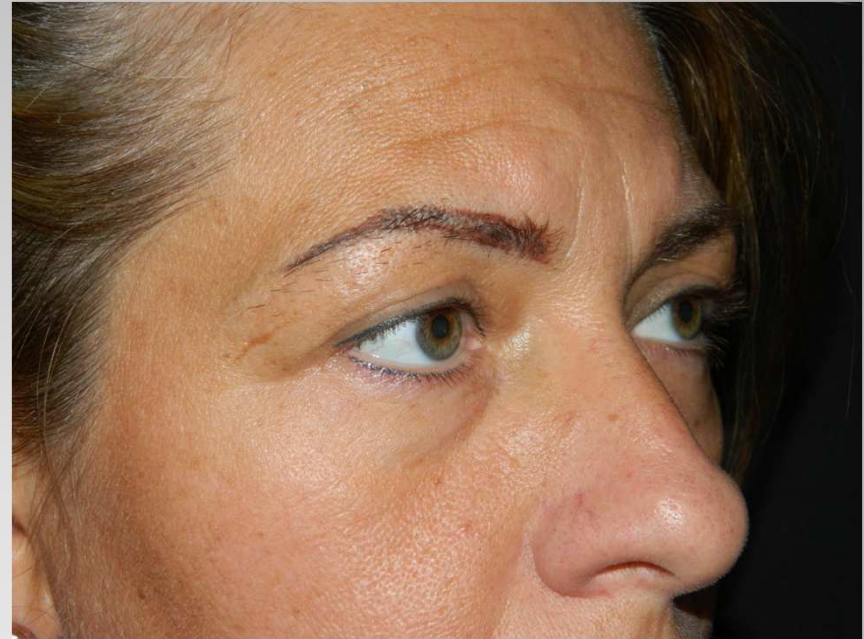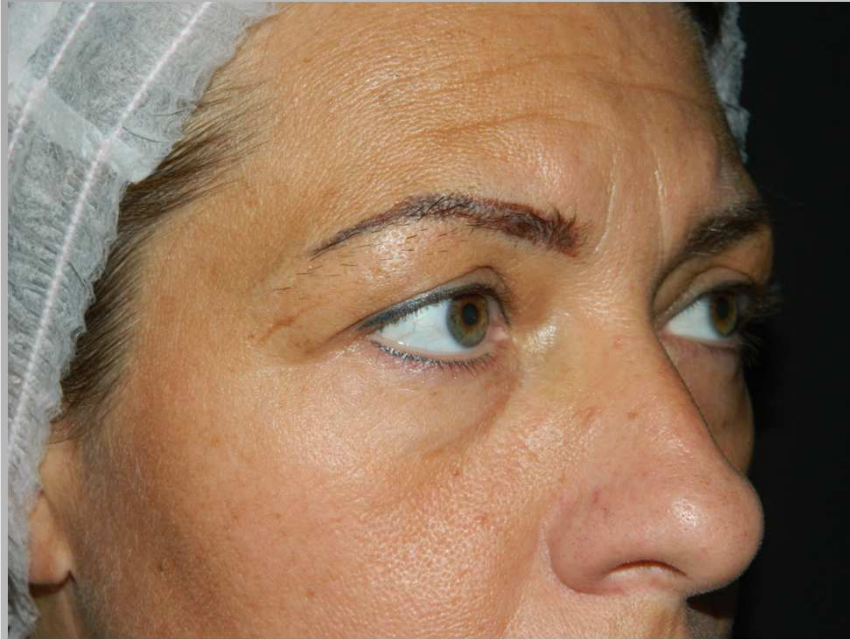1 application at 15 days



1 application at 12 days

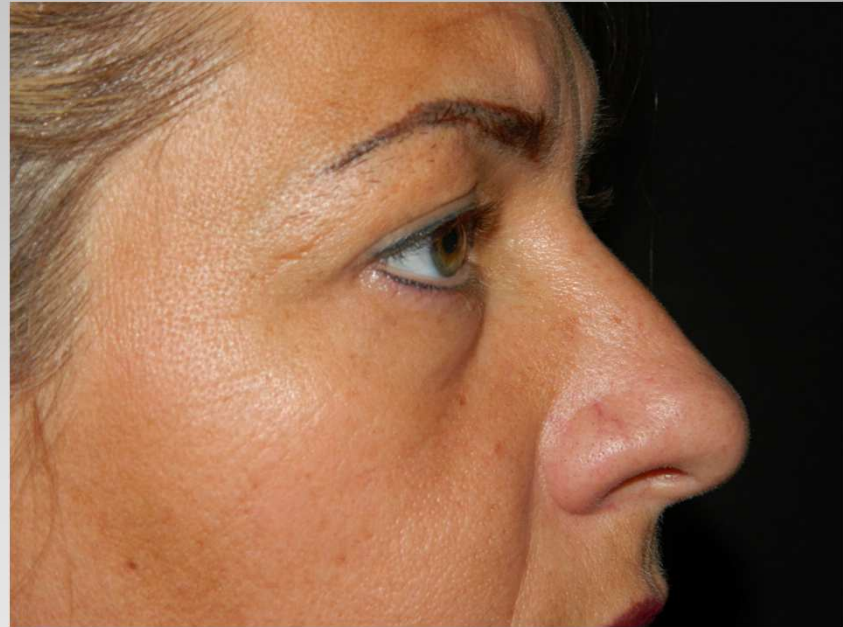
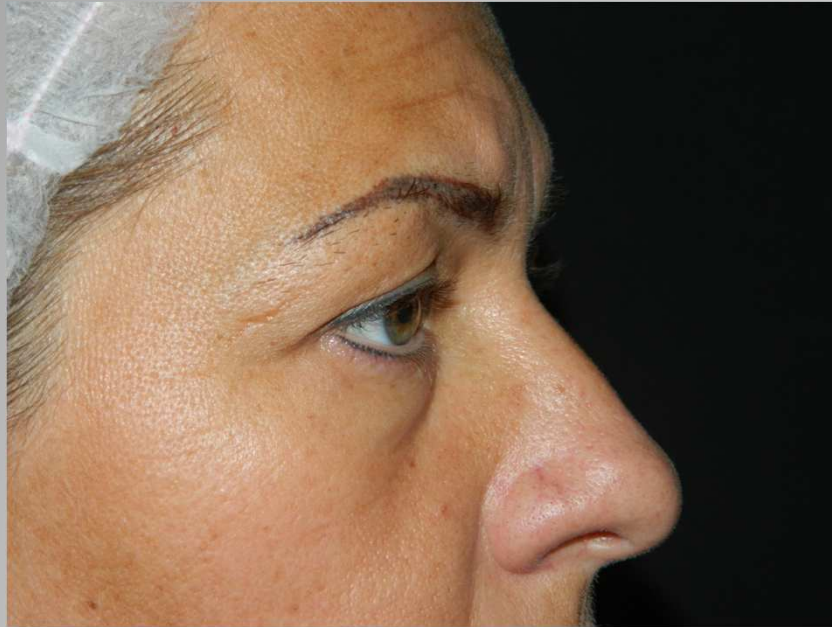
3 applications at 30/40 days



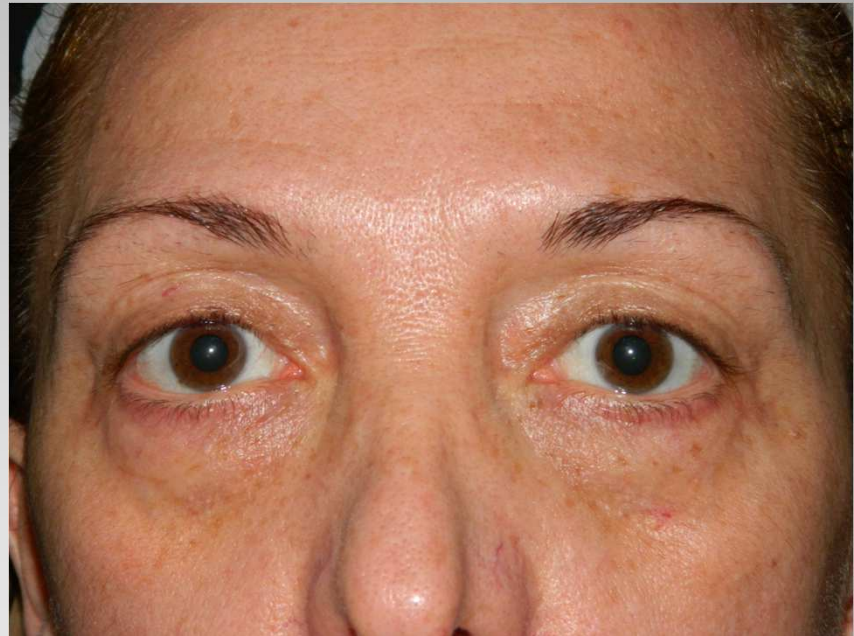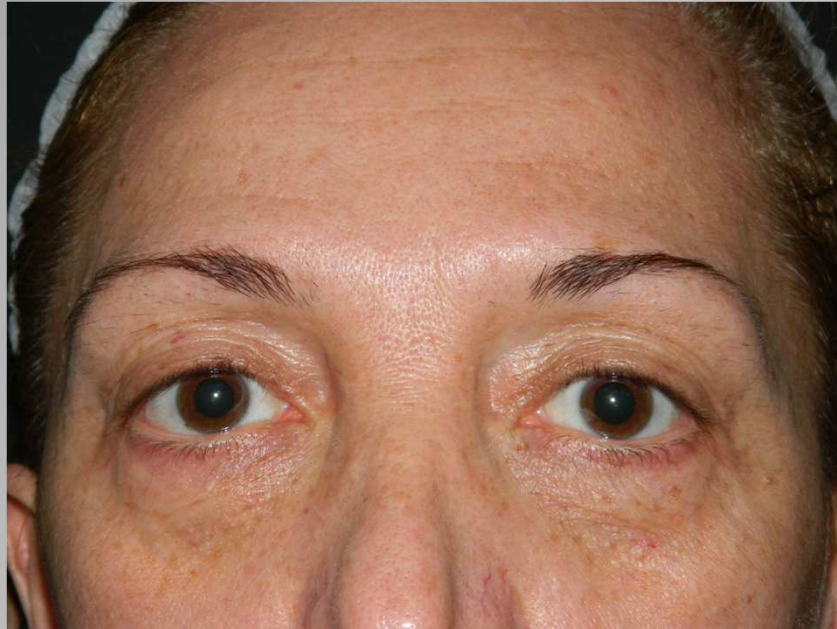3 applications at 30/40 days

leasemedica



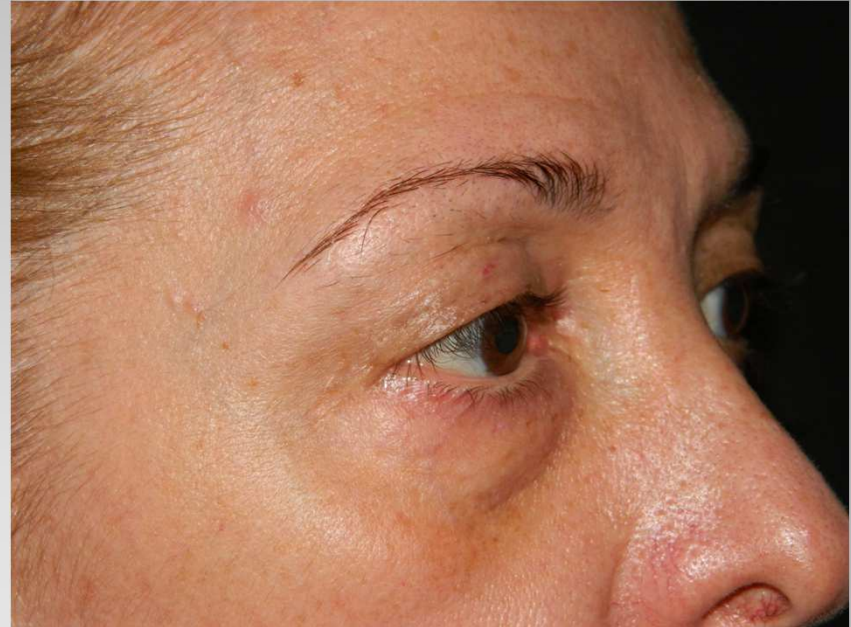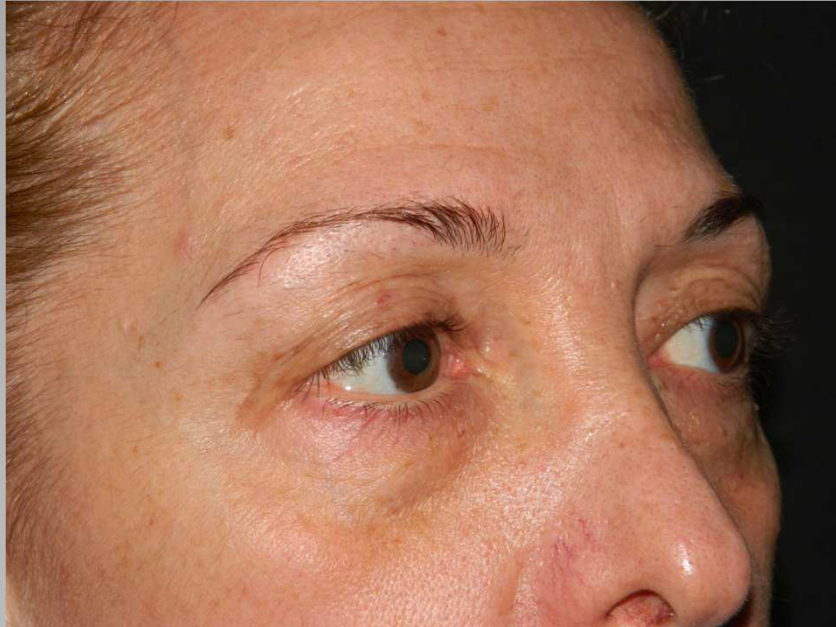3 applications at 30/40 days

lease**medica**



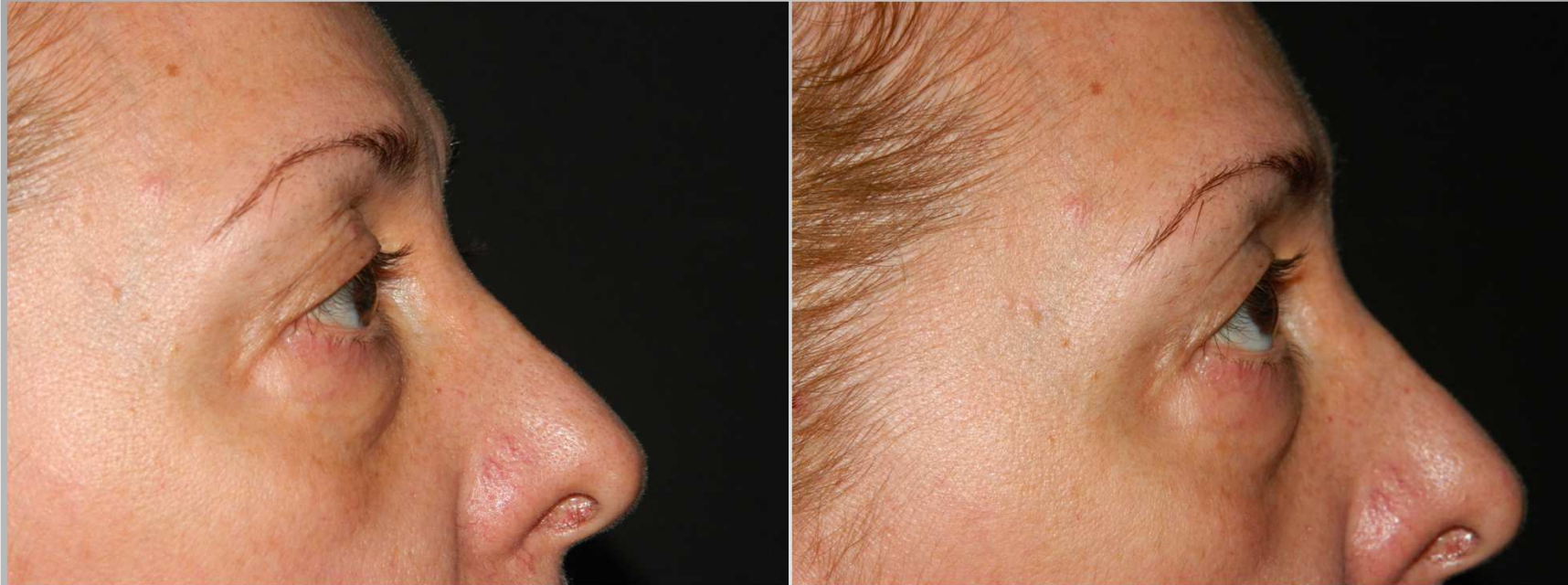2 applications at 30/40 days

lease**medica**



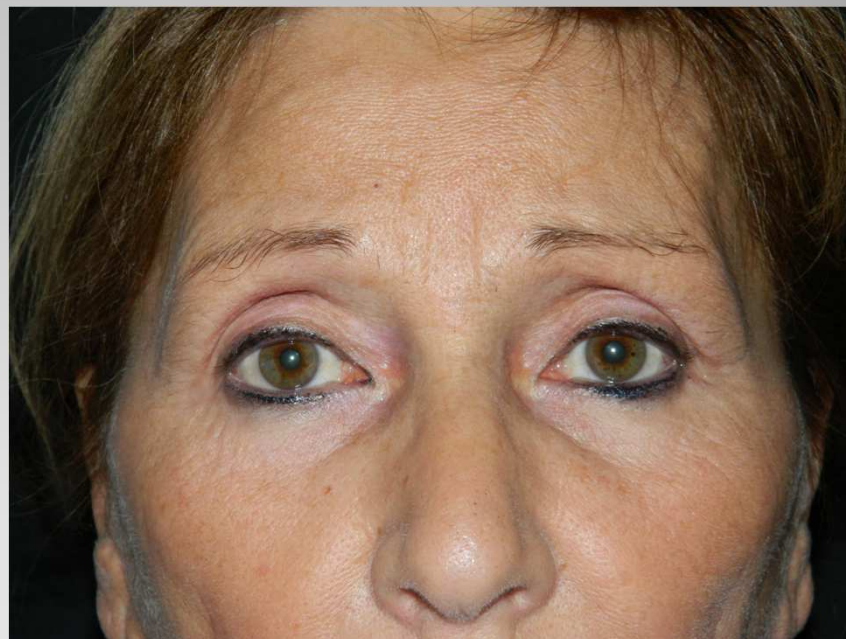
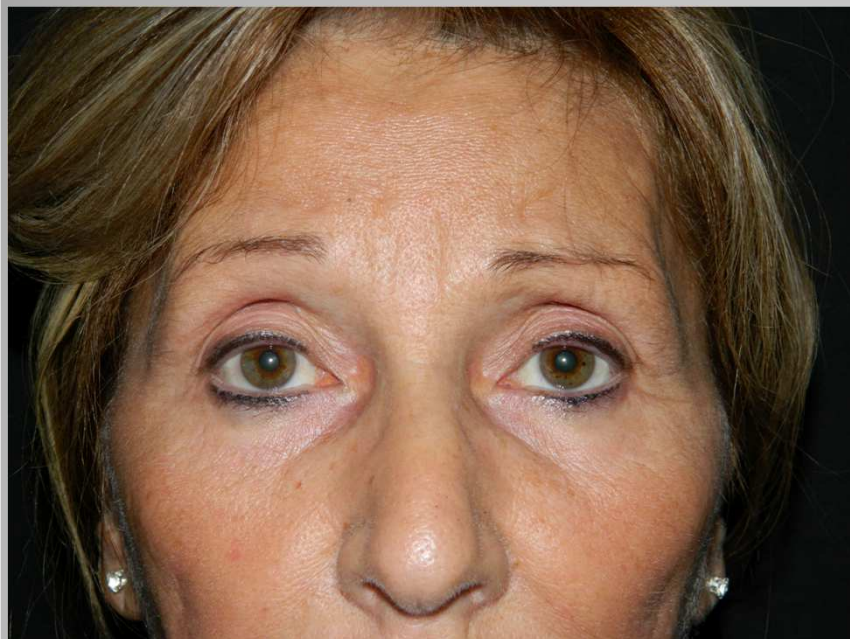
2 applications at 30/40 days

lease**medica**



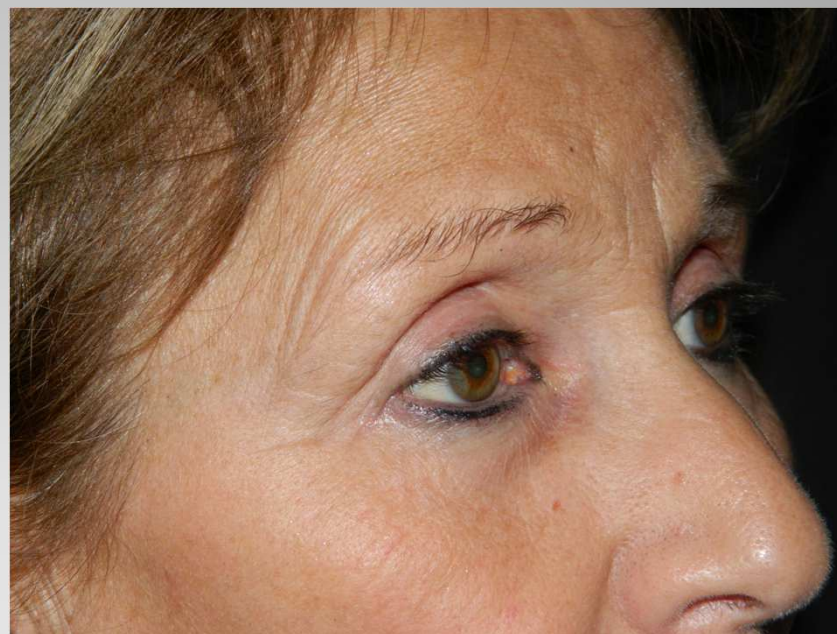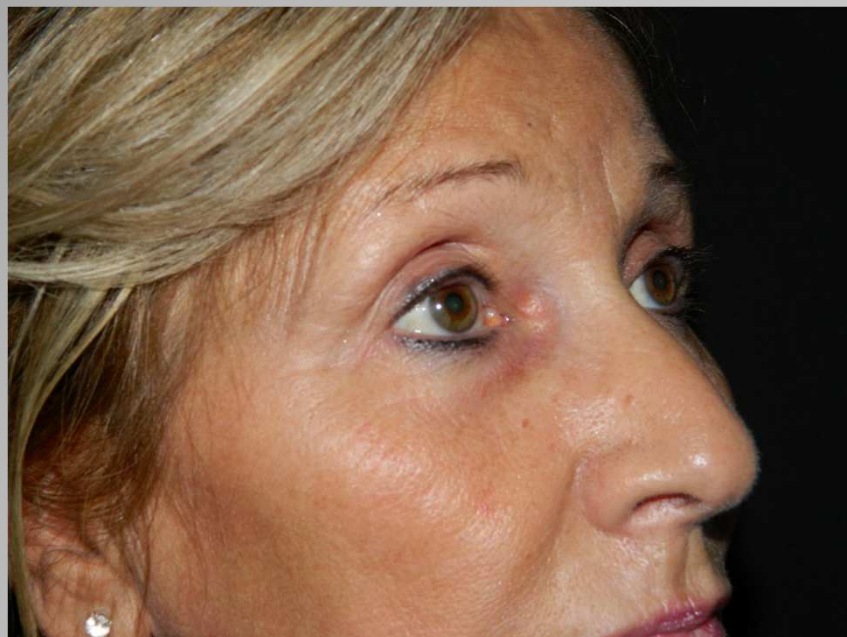2 applications at 30/40 days

lease**medica**



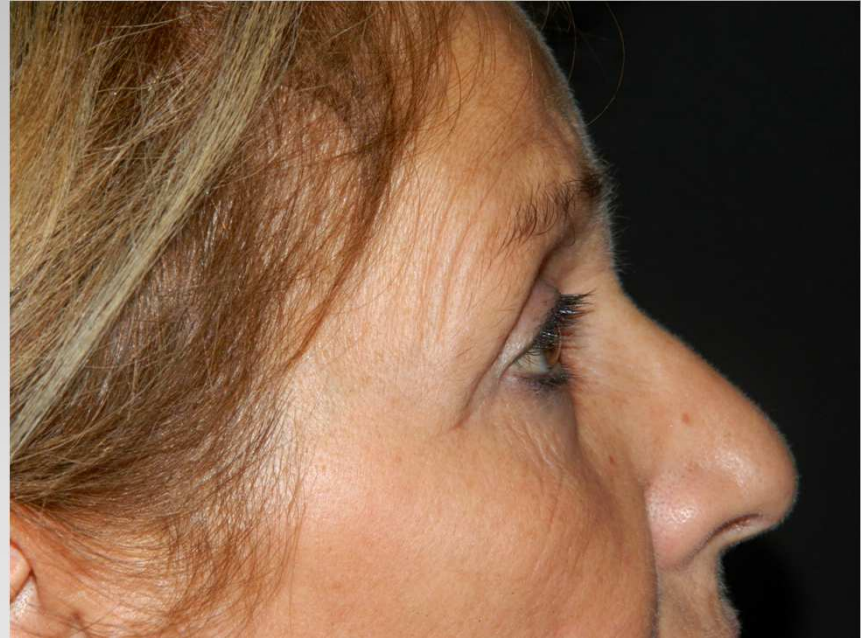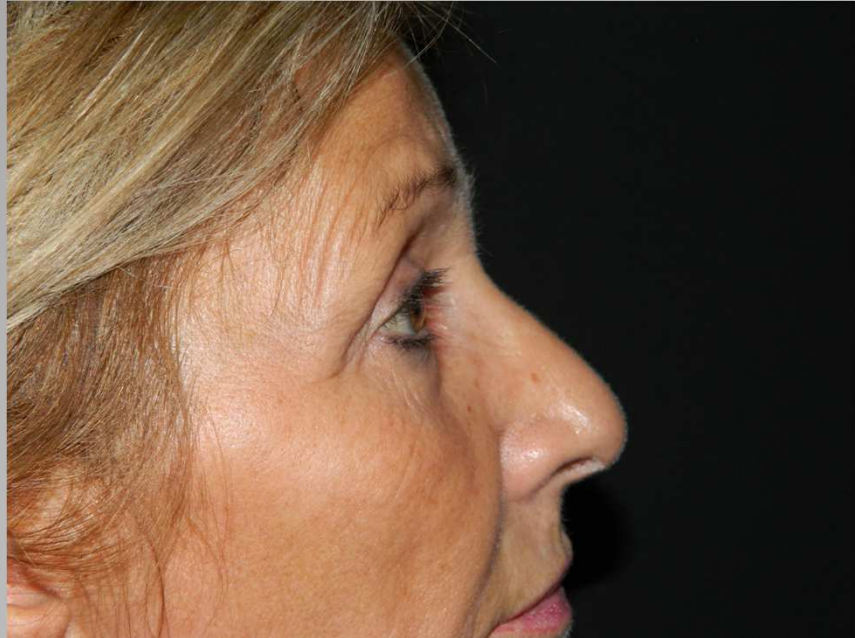1 application

lease**medica**



1 application

lease**medica**

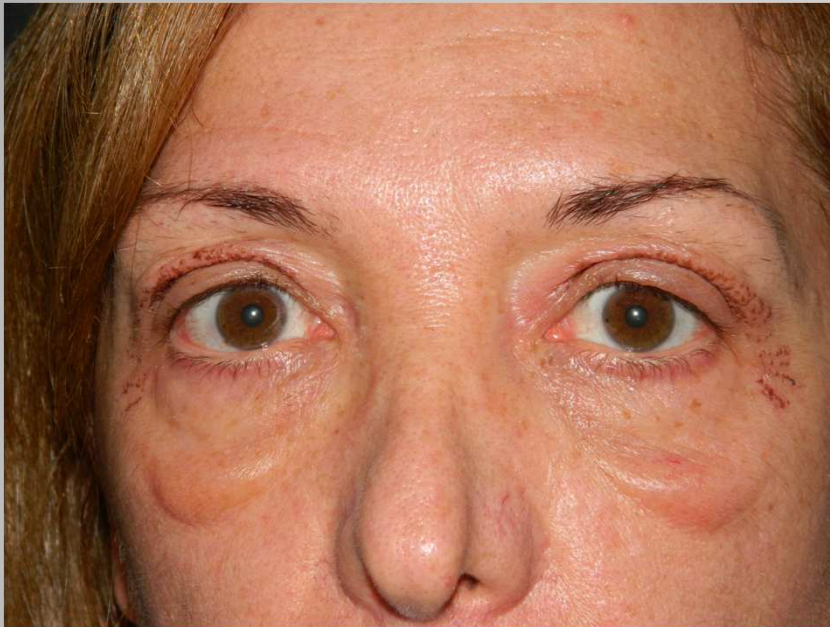

1 application

lease**medica**

Complications

Edema



patient after 2 days of treatment

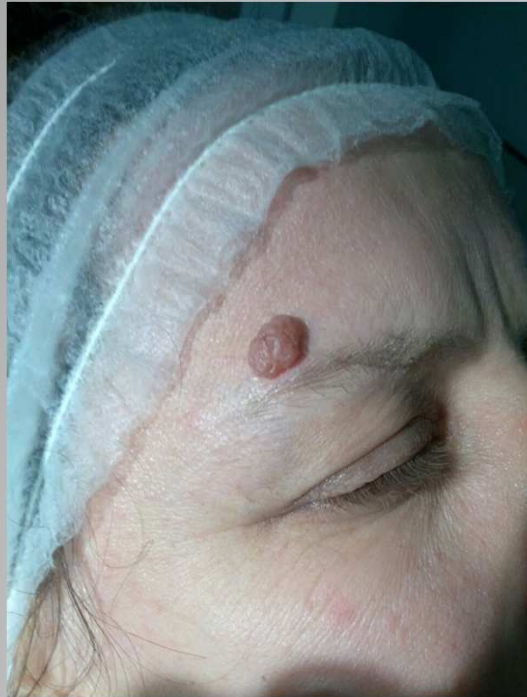Limits of the technique

fat bags under eyes

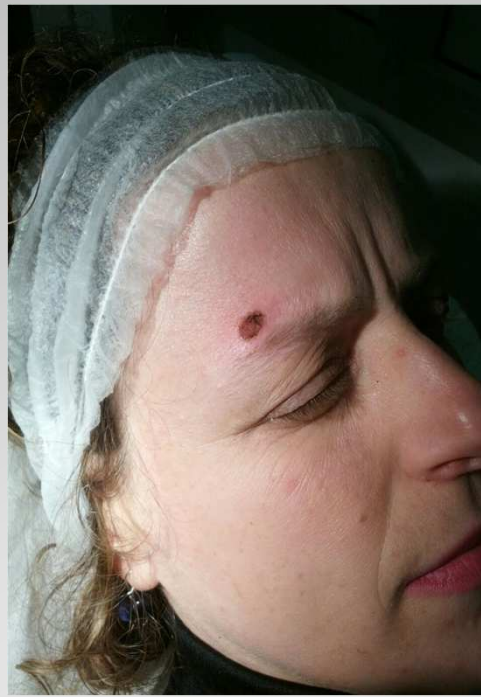excessive relaxation of the upper eyelid skin

Other indications of the same instrument

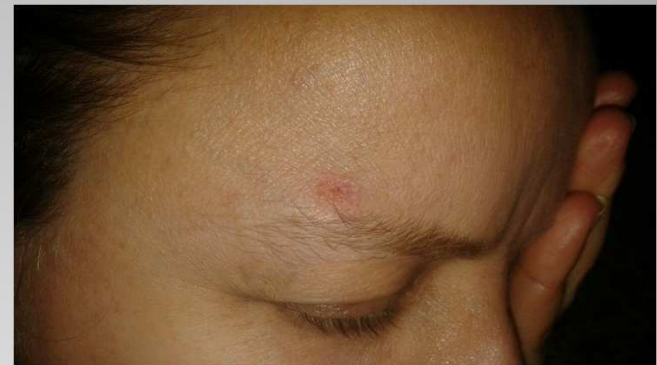- verrucae, fibroma, keloids, keratosis
- xanthelasma, naevus
- molluscum contagiosum
- striae expanses periumbilical,
- Scars and acne scars
- hyperpigmentation with epidermal thickening
- solar and senile lentigo



before

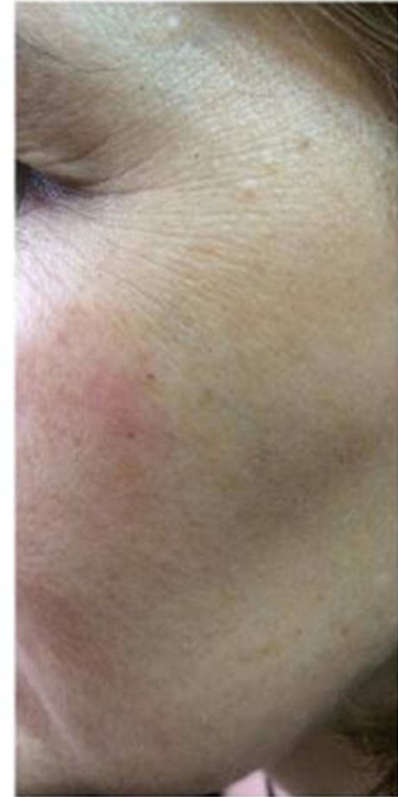
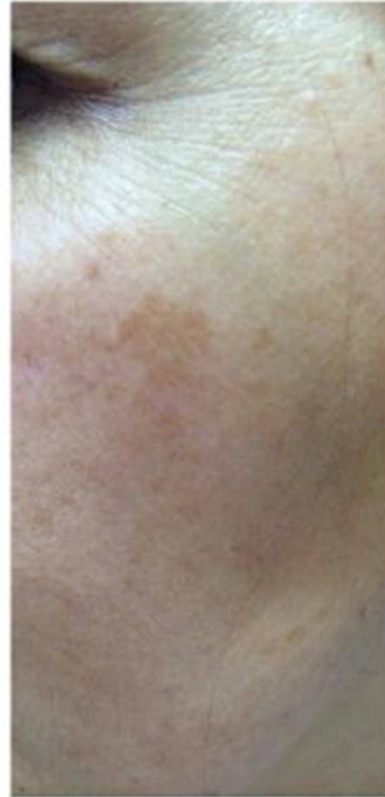
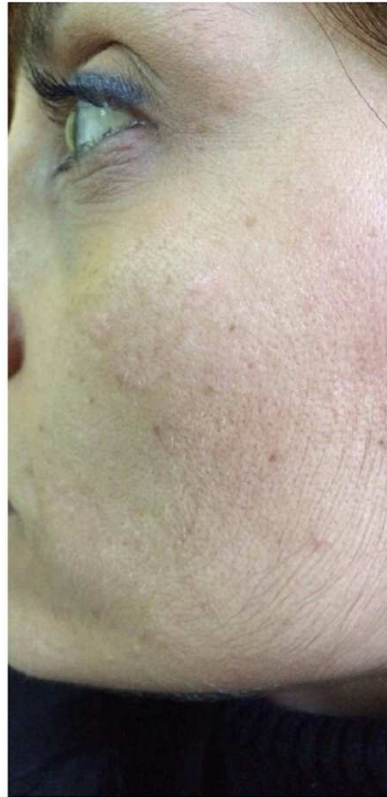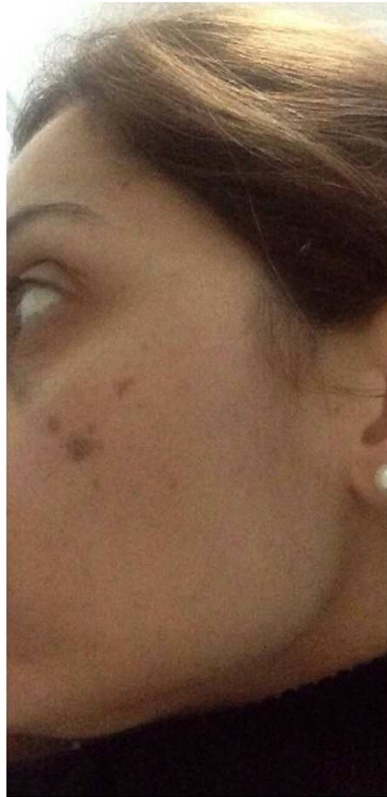after



after one week

Fibroma removal



lentigo removal